

# Novel Use of Erbium:YAG (2,940-nm) Laser for Fractional Ablative Photothermolysis in the Treatment of Photodamaged Facial Skin: A Pilot Study

MOSHE LAPIDOTH, MD, MPH,\*† MARINA EMIKO YAGIMA ODO, MD,‡ AND LILIAN MAYUMI ODO, MD‡

**BACKGROUND** The use of CO<sub>2</sub> or conventional erbium laser ablation or more recent nonablative laser photothermolysis for skin rejuvenation is associated with significant disadvantages.

**OBJECTIVE** The objective was to assess the efficacy of the erbium:YAG laser (2,940 nm) using the “ablative” fractional resurfacing mode to improve photodamaged skin.

**METHODS** A total of 28 patients, 27 women and 1 man, aged 28 to 72 years (mean age, 54.2 years), with Fitzpatrick Skin Types II to IV, were treated for mild to moderate actinic damage using fractional erbium:YAG laser (2,940 nm) combined with Pixel technology. Sessions were scheduled at 4-week intervals. Response to treatment was evaluated by two physicians on a five-tiered scale.

**RESULTS** Patients underwent one to four treatment sessions (mean, 3.2). The initial reaction consisted of erythema and minimal swelling. On clinical assessment 2 months after the final treatment, the results were rated excellent by 21 patients (75%) and good by 7 (25%). Nineteen of the 21 were also evaluated 6 to 9 months after final treatment without any significant change in the results.

**CONCLUSIONS** Fractional ablative photothermolysis using erbium:YAG laser (2,940 nm) is a promising option for skin resurfacing with reduced risk and downtime compared to existing laser methods.

*The equipment used in the Israel group only was loaned by Alma Lasers, Ltd.*

Fractional photothermolysis is a new technique for the treatment of skin lesions<sup>1</sup> in which an array of microscopic thermal wounds (microscopic treatment zones) is induced into the skin to stimulate a therapeutic response deep in the dermis. Nonablative fractional photothermolysis at a wavelength of 1,550 nm has been found to be effective for the treatment of melasma,<sup>2</sup> mild to moderate rhytides,<sup>3</sup> acne scars,<sup>4</sup> surgical scars,<sup>5</sup> and even poikiloderma of Civatte.<sup>6</sup> However, this “coagulative” approach is time-consuming and painful, and the results are not always predictable. Recently, “ablative” fractional photothermolysis using the erbium:YAG laser (2,940 nm) has been introduced as a novel means of providing treatment that would be as effective as traditional ablative approaches while avoiding their high downtime and risks. The laser produces thousands of microscopic, clinically inapparent wounds

on the skin surface that are rapidly reepithelialized by the surrounding, undamaged tissue, sparing the epidermis. The aim of this pilot study was to describe our clinical experience with this emerging technique.

## Subjects and Methods

The study group consisted of 18 women, who were treated in Israel, and 9 women and 1 man, who were treated in Brazil. Patients ranged in age from 28 to 72 years (mean, 54.2 years). All patients presented with mild to moderate actinic damage (solar lentiginosis, actinic keratosis, flat seborrheic keratosis, and fine wrinkles). Eight patients had Fitzpatrick Skin Type II, 12 had Type III, and 8 had Type IV. None of the patients had undergone skin resurfacing in the past. Exclusion criteria were photosensitivity, use of photosensitive medications, history of scarring,

\*Department of Dermatology, Rabin Medical Center, Petah Tiqwa, Israel; †Sackler Faculty of Medicine, Tel Aviv University, Tel Aviv, Israel; ‡Department of Dermatology, School of Medicine, University of Santo Amaro, San Paulo, Brazil

and use of isotretinoin in the previous year. Patients were provided with a detailed description of the purpose and possible outcomes of treatment and signed informed consent forms to participate in the study and to concede their permission for clinical photographs to be taken. All subjects signed the informed consent form before being enrolled to the study.

### Technique

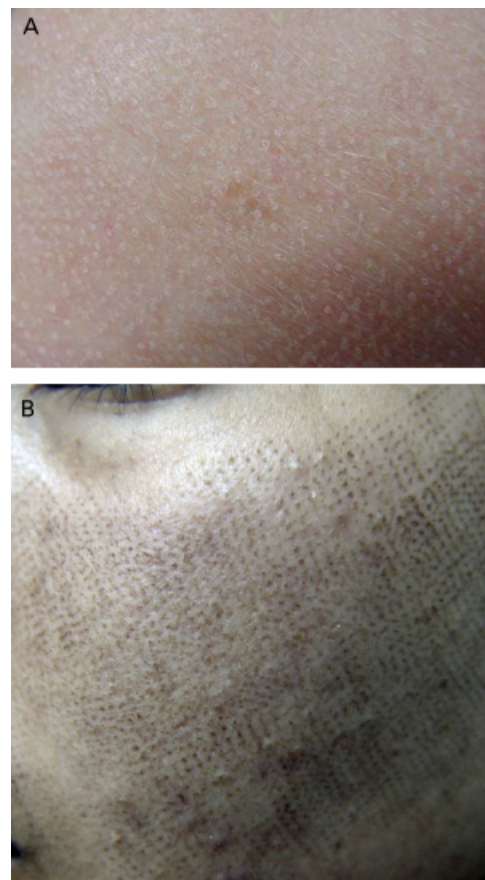
Patients were treated in the offices of the principal investigators using their existing treatment facilities. In 50% of the patients, according to patient's decision, treatment was carried out using a topical anesthetic cream (EMLA [eutectic mixture of lidocaine and prilocaine], AstraZeneca, London, UK) applied to the face under occlusion 2 hours before treatment. Fractional ablative photothermolysis treatment is carried out using a 2,940-nm Er:YAG laser (Pixel, Alma Lasers Ltd, Caesarea, Israel) that incorporates a microlens aligned in a matrix of either  $9 \times 9$  (81) dots (pixels), which emits 17 mJ/P per pixel, or  $7 \times 7$  (49) dots (pixels), which emits 28 mJ/P per pixel, with the maximum pulse energy output being 1,400 mJ/P. The single-pass ablation microzone of each pixel measures approximately 150  $\mu\text{m}$  in diameter and 120–140  $\mu\text{m}$  in depth. The laser microbeam passes through the matrixed microlens to interact with the skin surface without affecting the skin in the nonpixel zones. The total collateral microdamage depends on the number of passes, matrix size, and the level of energy used.

For this study, an Er:YAG laser device (Pixel, Alma Lasers Ltd) with  $7 \times 7$  (49-dot) alignment was used. Two to four stacked laser passes were performed for a penetration of 20  $\mu\text{m}$  (evaporative) 30  $\mu\text{m}$  (thermal) (1st pass), 35  $\mu\text{m}$  + 40  $\mu\text{m}$  (2nd pass), 50  $\mu\text{m}$  + 45  $\mu\text{m}$  (3rd pass), 60  $\mu\text{m}$  + 50  $\mu\text{m}$  and (4th pass; unpublished manufacturer's data) and a microzone diameter of 150  $\mu\text{m}$ . Treatment was given at 4-week intervals and continued until an acceptable end point was achieved. Biopsies were taken from the preauricular area in the Brazilian group before initiation of therapy; imme-

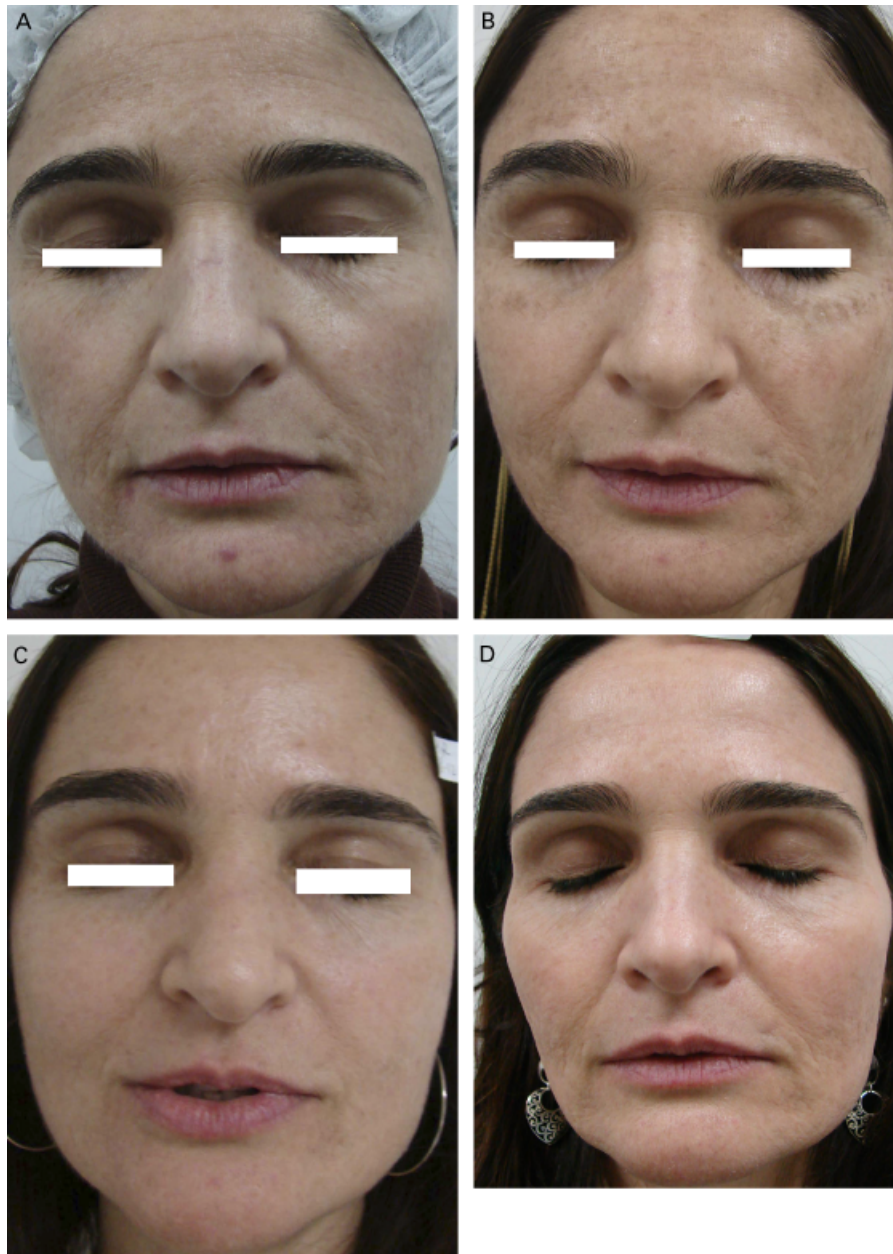diately after treatment; and 3, 7, and 60 days following the end of treatment.

### Follow-Up

Immediate follow-up examinations were performed after each session. Further follow-up was performed 2, 5, 7, 30, and 60 days posttreatment to monitor recovery, improvement, and any subsequent sequelae. Each patient was evaluated by the physician with respect to the severity of photodamage and wrinkles (wrinkle severity: no wrinkles = 1, completely wrinkled = 9) before treatment and at the 60-day follow-up. Textural irregularity was also evaluated by the physician at these time points. Side effects and complications were recorded. To evaluate skin improvement, photographs were taken with a digital camera (Sony T7, 5.1-megapixel resolution, Sony,



**Figure 1.** Immediately after treatment, “netlike” ablation with background erythema (A); 3 days after, darkening of the skin by exfoliated epidermis, in a “net” pattern (B).



**Figure 2.** Before treatment (A); 7 days posttreatment (B); 60 days posttreatment (C); 9 months posttreatment (D).

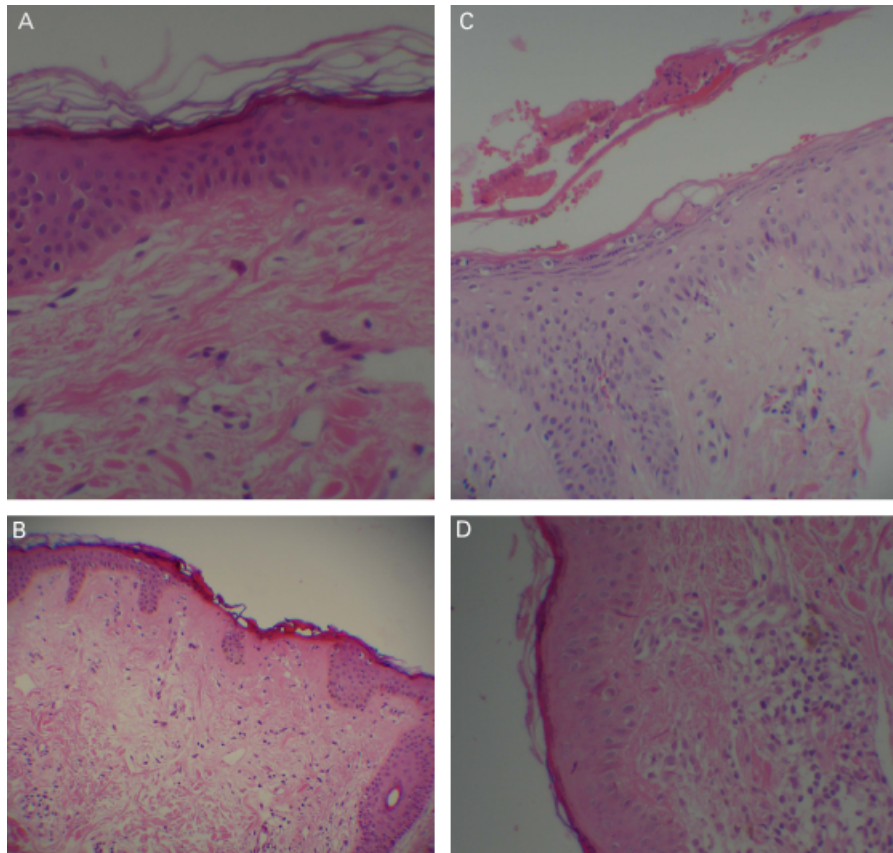
Tokyo, Japan) before treatment and at each follow-up visit. The photographs taken before initiation of treatment and 60 days following the end of treatment were independently evaluated and compared by a plastic surgeon and a dermatologist or two dermatologists, who graded the results on a five-tiered scale, as follows: excellent, 75% to 100% lesion clearance and textural improvement; good, 50% to 75% improvement; fair, 25% to 50% im-

provement; poor, <25% improvement; or worse, final results were worse than the pretreatment findings. Nineteen of the 21 were also evaluated 6 to 9 months after final treatment.

### Results

All 28 patients completed the study. The number of treatment sessions ranged from 1 to 4 (mean, 3.2).





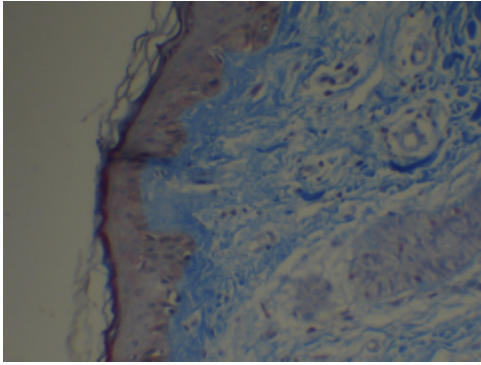
**Figure 3.** Normal skin before treatment (A); immediately after, coagulation of epidermis and top of superior dermis (B); 3 days after, crust of coagulated epidermis is being eliminated and epidermis restored (C); 7 days after, normal epidermis and inflammatory infiltrate in the dermis (D). Original magnification,  $\times 100$ .

At the clinical assessment carried out 2 months after the last treatment session, outcome was rated excellent in 21 patients (75%) and good in 7 (25%). No cases were graded as fair, poor, or worse. In all patients, the initial reactions to treatment consisted of erythema and minimal swelling in the treated areas; the patients reported a burning sensation but no significant pain. The erythema lasted between 2 and 10 days (mean, 3.6 days), and its severity was correlated with the number of laser passes. Overall, erythema was mild without any downtime. No permanent side effects were noted. (A typical patient's follow-up is illustrated in Figures 1 and 2). The biopsy samples clearly showed the epidermal and upper dermal ablation and healing process with collagen regrowth as highlighted by Masson's trichrome stain (Figures 3 and 4). In the 19 of the 21

that were evaluated also 6 to 9 months after final treatment, there was not any significant change in the results.

### Discussion

This study reports the outcome of 28 patients treated with ablative fractional laser photothermolysis (2,490 nm) for photodamaged skin. Although ablative resurfacing with the CO<sub>2</sub> or Er:YAG laser remains the gold standard in skin rejuvenation,<sup>7</sup> it is associated with considerable downtime and a risk of prolonged erythema, infection, scarring, and delayed hypopigmentation.<sup>8,9</sup> Moreover, it is painful and usually requires general anesthesia. In the search for alternatives that would also promote some collagen regrowth,<sup>8</sup> researchers first turned to nonablative



**Figure 4.** 2 months after treatment: the collagen Masson's trichrome stain demonstrates new bands of collagen in the superior dermis.

and intense pulsed light lasers. These were found to be safe but limited in efficacy, and the results were not comparable to ablative resurfacing.<sup>9–12</sup>

In 2003, Manstein and colleagues<sup>1</sup> introduced the concept of fractional photothermolysis to bridge the gap between ablative and nonablative resurfacing. Local resurfacing with a 1,550-nm nonablative laser using an array of microscopic thermal wounds proved effective, and downtime and morbidity were minimal. However, the procedure required multiple sessions and local anesthesia, and the results were sometimes variable.<sup>13–16</sup> This article describes a novel modification of the fractional photothermolysis technique, from “bulk ablation” to “localized ablation,” wherein only a small fraction of the skin is treated. The laser is used to produce thousands of microscopic, clinically inapparent, thermal wounds in the skin, while the intact, undamaged skin around each wound acts as a reservoir, allowing relatively rapid reepithelialization of the treatment zone with, consequently, little risk of infection and scarring. On the basis of the present results, fractional ablative photothermolysis appears to be at least as effective as nonablative procedures, and the outcome is predictable. It is noteworthy that hyperpigmentation, a particularly troublesome side effect of ablative laser resurfacing, was not noted in our patients, although the follow-up was relatively short. We speculate that the microscopic pattern of injury induced by the 2,490-nm laser caused only minimal inflammation

and therefore led to fewer clinically evident pigmentary changes. Nevertheless, hyperpigmentation is a long-term sequela of laser treatment, and extended follow-up is required before it can be completely ruled out. Further comparative studies with 1,550-nm fractional photothermolysis are also needed to confirm the efficacy and safety of this new technique. It should be emphasized that the system presented in this study is a “stamped” fractional photothermolysis technique compared to scanning fractional photothermolysis that requires a scanner and, in some systems, expensive consumables.

In conclusion, Er:YAG laser fractional photocoagulation is a promising option for the treatment of various dermatologic conditions, avoiding the adverse effects of ablative laser procedures while improving the limited efficacy of the nonablative ones.

*Acknowledgment* We thank Gloria Ginzach for her editorial and secretarial assistance.

## References

1. Manstein D, Herron GS, Sink RK, et al. Fractional photothermolysis: a new concept for cutaneous remodeling using microscopic patterns of thermal injury. *Lasers Surg Med* 2004;34:426–38.
2. Geronemus RG. Fractional photothermolysis: current and future applications. *Lasers Surg Med* 2006;38:169–76.
3. Rokhsar CK, Fitzpatrick RE. The treatment of melasma with fractional photothermolysis: a pilot study. *Dermatol Surg* 2005;31:1645–50.
4. Hasegawa T, Matsukura T, Mizuno Y, et al. Clinical trial of a laser device called fractional photothermolysis system for acne scars. *J Dermatol* 2006;33:623–7.
5. Behroozan DS, Goldberg LH, Dai T, et al. Fractional photothermolysis for the treatment of surgical scars: a case report. *J Cosmet Laser Ther* 2006;8:35–8.
6. Behroozan DS, Goldberg LH, Glaich AS, et al. Fractional photothermolysis for treatment of poikiloderma of Civatte. *Dermatol Surg* 2006;32:298–301.
7. Ross EV, Miller C, Meehan K, et al. One-pass CO<sub>2</sub> versus multiple-pass Er:YAG laser resurfacing in the treatment of rhytides: a comparison side-by-side study of pulsed CO<sub>2</sub> and Er:YAG lasers. *Dermatol Surg* 2001;27:709–15.
8. Hruza GJ, Dover JS. Laser skin resurfacing. *Arch Dermatol* 1996;132:451–5.

9. Rostan EF. Laser treatment of photodamaged skin. *Facial Plast Surg* 2005;21:99–109.
10. Goldberg DJ, Whitworth J. Laser skin resurfacing with the Q-switched Nd:YAG laser. *Dermatol Surg* 1997;23:903–6.
11. Herne KB, Zachary CB. New facial rejuvenation techniques. *Semin Cutan Med Surg* 2000;19:221–31.
12. Menaker GM, Wrone DA, Williams RM, et al. Treatment of facial rhytids with a nonablative laser: a clinical and histologic study. *Dermatol Surg* 1999;25:440–4.
13. Marra DE, Yip D, Fincher EF, et al. Systemic toxicity from topically applied lidocaine in conjunction with fractional photothermolysis. *Arch Dermatol* 2006;142:1024–6.
14. Fisher GH, Kim KH, Bernstein LJ, et al. Concurrent use of a handheld forced cold air device minimizes patient discomfort during fractional photothermolysis. *Dermatol Surg* 2005;31(9 Pt 2):1242–3; discussion 1244.
15. Fisher GH, Geronemus RG. Short-term side effects of fractional photothermolysis. *Dermatol Surg* 2005;31(9 Pt 2):1245–9; discussion 1249.
16. Laubach HJ, Tannous Z, Anderson RR, et al. Skin responses to fractional photothermolysis. *Lasers Surg Med* 2006;38:142–9.

---

Address correspondence and reprint requests to: Moshe Lapidot, MD, Head, Laser Unit, Department of Dermatology, Rabin Medical Center, Golda Campus, Petah Tiqwa 49372, Israel, or e-mail: [alapidot@netvision.net.il](mailto:alapidot@netvision.net.il)