

A 2940 nm Fractional Photothermolysis Laser in the Treatment of Acne Scarring: A Pilot Study in China

Hui Deng MD PhD,^{a,b} Dingfen Yuan MD,^a Chunlin Yan MD,^b Xiaoxi Lin MD PhD,^c Xu'an Ding MD^a

^aDepartment of Dermatology, The Sixth People's Hospital of Shanghai, Shanghai Jiaotong University, Shanghai, China

^bDepartment of Dermatology, Huashan Hospital, Fudan University, Shanghai, China

^cDepartment of Plastic and Reconstructive Surgery, The Ninth People's Hospital, Shanghai Jiaotong University, Shanghai, China

ABSTRACT

Objective: To evaluate the efficacy and safety of a 2940 nm fractional photothermolysis laser in the treatment of acne scarring in Chinese people.

Methods: Twenty-six patients with moderate-to-severe atrophic scarring were treated with a 2940 nm-wavelength fractional photothermolysis laser.

Results: All patients had encouraging results. Both skin elasticity and moisture content increased significantly after five treatments. In post-treatment evaluations, both the patients treated, as well as an independent group of physicians each scored the atrophic scar improvement as significant.

Conclusion: The 2940 nm fractional photothermolysis laser is safe and effective in the treatment of acne scarring.

INTRODUCTION

Post-acne scarring can be a physically challenging and psychologically devastating condition. Unfortunately, there are few treatment options. Fractional photothermolysis (FP) is a new and innovative laser technology in the treatment of acne scarring. FP creates multiple, ablative, thermal channels in the skin that are left surrounded by untreated, intervening skin that aids in rapidly healing the injured tissue. This study evaluated the efficiency and safety of a new 2940 nm FP laser in the treatment of atrophic acne scarring.

PATIENTS, MATERIALS AND METHODS

Twenty-six patients (ages 25–37 years; Fitzpatrick skin types III–IV) with moderate-to-severe atrophic scarring were treated with a 2940 nm-wavelength FP laser (Pixel[®] 2940, Alma Lasers Ltd., Caesarea, Israel). Patients with a history of keloid formation or oral isotretinoin use within six months before treatment were excluded. The treatment area was thoroughly cleansed with mild soap before each procedure. Five treatment sessions at three-week intervals were performed. Each treatment involved a fluence of 800–1400 mJ/cm² at a density of 49 pixels/cm² applied to the scarred area using 8–10 passes. Treatment parameters were selected to deliver high-pulse energies to maximize penetration depth for optimum results, and then adjusted based on each patient's pain threshold.

The treatment responses were evaluated using three methods: quantitative analysis, physician assessment and patient self-assessment. Skin elasticity, skin moisture content, as well as the number of pores within the treatment area were calculated us-

ing white and UV light (VisioFace[®] Skin Check System, Courage & Khazaka Electronic GmbH, Cologne, Germany). High-resolution digital photographs were taken at baseline and again six months after the final treatment. All photographs were taken in a standardized manner, without a flash, using macrolens settings. Pre- and post-treatment photographs were assessed by three non-treating, blinded, independent observers using the following weighted scale: 3 points for deep scars, 2 points for shallow scars and 1 point for superficial scars. For each patient, corresponding 10 × 10-cm² grids from before-and-after pictures were graded for overall scar severity using this scale. Observers also counted the number of each type of acne scar (rolling—least severe, boxcar—more severe, and ice pick—most severe) and then multiplied each number by its weighting factor (rolling=1×; boxcar=2×; ice pick=3×), yielding the overall score.¹ As a third evaluation measurement, patients were asked to assess their improvement using the following five-point scale: 0=no or minimal improvement (0%–10%); 1=slight improvement (11–25%); 2=moderate improvement (26–50%); 3=significant improvement (51–75%); and 4=substantial improvement (>75%). Patient assessments were gathered using phone interviews or written questionnaires, completed six months after the final treatment.

Temporary side effects such as, pain, redness, pigmentary change and other adverse events were also evaluated. Immediately after each laser treatment, subjects assessed pain, while the treating physician assessed purpura, edema and erythema. A scale of 0–3 was used, with 0=none, 1=mild, 2=moderate, and 3=severe pain, swelling, edema, or erythema.

Using the same scale six months after the fourth treatment, the treating physician also evaluated potential side effects of hyper- or hypo-pigmentation, or scarring.

The data were collected and analysed using the Student's paired *t* test with a significance level of 0.05.

RESULTS

Skin Elasticity, Moisture Content and The Number of Pores

Skin elasticity and moisture content were significantly improved, and the number of pores decreased significantly following the course of treatments (Table 1).

Physician Assessment

Acne scarring improved in 100% of the twenty-six patients completing the study (Figure 1). Scar severity scores (baseline versus six months after the final treatment) improved by a mean of 79.81%.

Patient Self-Assessment

Patients reported significant scar reduction at six months after the last laser treatment—subjective scar improvement was in the range of 50% to 80%. All patients reported being satisfied with their treatment results, and all stated that they would be willing to undergo treatment again. Two patients (both female) noted following treatment that their acne scars were “shallower” and easier to conceal with makeup.

Adverse Events

Treatments were well tolerated by all patients. Treatment-induced erythema was characterized by all subjects as being both mild and transient and lasted about three days. No patients reported blistering, persistent swelling or any other adverse

events. Of the 16 patients who returned for follow-up six months after their last treatment, none reported any delayed-onset changes in skin pigmentation, erythema or increased skin sensitivity (Table 2).

DISCUSSION

Acne scarring is a complex problem that is not amenable to a simple, definitive solution. Depending on specific patient features and preferences, a combination of several treatment procedures may be appropriate. A therapeutic alliance with the patient is necessary to ensure patience and compliance during the often long and occasionally frustrating treatment course.²

Recently, a new technology called fractional photothermolysis (FP) has been used in the treatment of acne scarring and other conditions.³⁻⁹ FP works by delivering an array of microscopic thermal wounds at controllable depths into the dermis. The technique coagulates both the epidermis and dermis without affecting the stratum corneum, which acts as a bandage that protects the tiny wounds as they heal. The first medical laser to utilize fractional photothermolysis technology is known as Fraxel[®] (Solta Medical, Inc., Hayward, CA). The device employs a 1550 nm, non-ablative erbium fiber laser and has been demonstrated to be efficient in the treatment of acne scarring. But as a non-ablative laser, it has limitations such as increased pain, a longer treatment course and increased possibility of hyperpigmentation in Asian people. To minimize these side effects, scientists later applied fractional photothermolysis using an ablative laser in order to reduce side effects and promote a faster re-epithilization rate.⁸ Because the 2940 nm wavelength of the Erbium:YAG laser is highly absorbed by water-rich tissue, this laser can ablate skin with minimal residual thermal damage,

FIGURE 1. The effect of the Pixel[®] 2940 FP Er:YAG laser on scar severity scores.

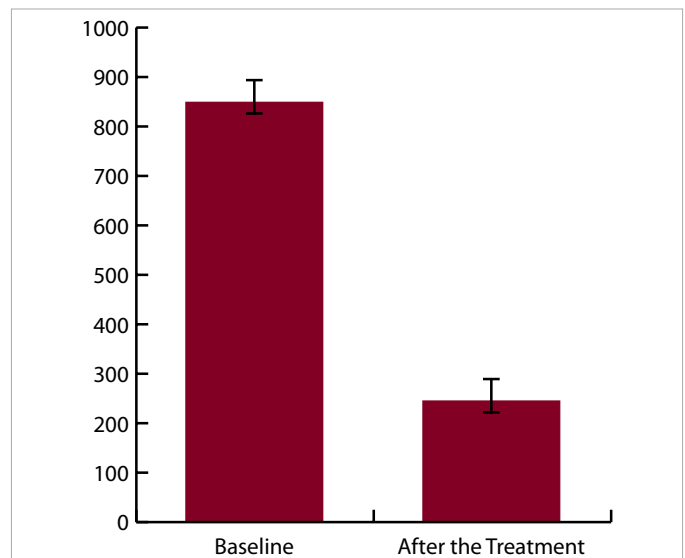


TABLE 1.

The Effect of Pixel on the Skin Elasticity: The Moisture and Number of Pores			
	Elasticity (%)	Skin Moisture (%)	Number of Pores
Baseline	52.1±5.1	35.4±5.1	478±96
Six months After the Treatment	74.8±7.0	64.1±7.8	169±37

TABLE 2.

Temporary Side Effects Caused by Pixel 2940 FP Treatment	
Pain	Mean=1 ± 0.2
Crusting (days)	Mean=3.1 ± 1.2
Erythema (days)	Mean=3.6 ± 1.5
Swelling (days)	Mean=1.0 ± 0.6
Hyperpigmentation	0/26
Hypopigmentation	0/26
Scar Formation	0/26

thereby potentially minimizing the risks of post-inflammatory hyperpigmentation and other side effects.⁹

In conclusion, our results support the use of a 2940 nm FP laser as a safe, effective treatment for facial acne scarring. Scar improvement was noted in all treated subjects, with minimal discomfort. Acne scarring improved in 100% of the 16 patients completing the study. Scar severity scores improved by a mean of 79.81%, and all patients reported subjective scar improvement of at least 50%. No treatment-related adverse events were observed. This protocol appears to be most effective in reducing scar depth and softening scar contours, although the optimal treatment protocol has yet to be determined. Future studies of this device for the treatment of acne scarring should address long-term clinical improvement, biochemical markers of efficacy, and optimal treatment parameters.

DISCLOSURES

The authors have no relevant conflicts of interest to disclose.

REFERENCES

1. Lipper GM, Perez M. Nonablative acne scar reduction after a series of treatments with a short-pulsed 1,064 nm neodymium:YAG laser. *Dermatol Surg*. 2006;32(8):998-1006.
2. Goodman GJ, Baron JA. The management of postacne scarring. *Dermatol Surg*. 2007;33(10):1175-1188.
3. Alster TS, Tanzi EL, Lazarus M. The use of fractional laser photothermolysis for the treatment of atrophic scars. *Dermatol Surg*. 2007;33(3):295-299.
4. Kim DH, Lee SJ, Kang JM, et al. Cracks on the tip: An unusual complication using the fractional photothermolysis system. *J Eur Acad Dermatol Venereol*. 2007;21(9):1280-1281.
5. Naito SK. Fractional photothermolysis treatment for resistant melasma in Chinese females. *J Cosmet Laser Ther*. 2007;9(3):161-163.
6. Mezzana P, Valeriani M. Rejuvenation of the aging face using fractional photothermolysis and intense pulsed light: A new technique. *Acta Chir Plast*. 2007;49(2):47-50.
7. Chiu RJ, Kridel RW. Fractionated photothermolysis: The Fraxel 1550 nm glass fiber laser treatment. *Facial Plast Surg Clin North Am*. 2007;15(2):229-237.
8. Hantash BM, Mahmood MB. Fractional photothermolysis: A novel aesthetic laser surgery modality. *Dermatol Surg*. 2007;33(5):525-534.
9. Kopelman J. Erbium: YAG laser—An improved periorbital resurfacing device. *Semin Ophthalmol*. 1998;13(3):136-141.

ADDRESS FOR CORRESPONDENCE

Hui Deng, MD, PhD

Department of Dermatology
The Sixth People's Hospital of Shanghai,
Shanghai Jiaotong University
Yishan Road 600
Shanghai, China 200233
E-mail:.....denghui_1@hotmail.com